



AUTOPSY REPORT

Case No. ML19-0331

January 29, 2019




ON THE BODY OF

Rhogenia Ann Nicholas

CAUSE OF DEATH: Gunshot wounds of the torso and right lower extremity

MANNER OF DEATH: Homicide

DATE OF DEATH: January 28, 2018

		03/12/19
	-----	MMDDYY
	Marianne E. Beynon, M.D. Forensic Pathology Fellow	
Reviewed by:		03/13/19
	-----	MMDDYY
	Dwayne A. Wolf, M.D., Ph.D. Deputy Chief Medical Examiner	
Reviewed by:		3-19-19
	-----	MMDDYY
	Mary L. Anzalone, M.D. Assistant Medical Examiner	

## POSTMORTEM EXAMINATION ON THE BODY OF

Rhogena Ann Nicholas

**HISTORY:** The decedent, a 58-year-old white female, sustained multiple gunshot wounds during the serving of a narcotic search warrant at her residence, and was declared deceased at the scene at 5:15 p.m. on January 28, 2018. Identification was confirmed by fingerprint comparison. See companion case ML19-0330.

**AUTOPSY:** The autopsy is performed at the Harris County Institute of Forensic Sciences by Forensic Pathology Fellow Marianne E. Beynon, M.D. under the supervision of Deputy Chief Medical Examiner Dwayne A. Wolf, M.D., Ph.D., pursuant to Article 49.25, Texas Code of Criminal Procedure, beginning at 9:30 a.m. on January 29, 2019.

### EXTERNAL APPEARANCE:

**CLOTHING:** When first viewed, the decedent is clad in a purple T-shirt, a black bra, blue jean pants, and blue and green underwear. A black watch encircles the left wrist. Dog hair is on the clothing and the skin. The clothing has defects corresponding to the gunshot wounds; see EVIDENCE OF INJURY. The hands are bagged. The body is lying in a white body transport bag. Harris County morgue identification bands encircle the right wrist and left ankle. A Harris County morgue tracking device encircles the left ankle.

The body is that of a normally developed, thin, white female who weighs 128 pounds, is 69 inches in length (body mass index of 18.9 kilograms per square meter), and appears compatible with the reported age of 58 years. The body is cool, subsequent to refrigeration. Rigor mortis is fully developed and symmetrical. Partially fixed, faint pink-red lividity extends over the posterior surfaces of the body except in areas exposed to pressure.

The scalp hair is graying-brown, straight, and measures up to 14 inches in length. The irides are brown. The corneas are clear. The sclerae are white. The conjunctivae and oral mucosa are without petechial hemorrhages. The external auditory canals, external nares, and oral cavity are free of foreign material and abnormal secretions. The nasal septum is palpably intact. The lips are dry, and otherwise unremarkable. The teeth

are natural and in poor condition, with absent maxillary teeth and few remaining mandibular teeth. Makeup is on the face, including foundation, blush, eyeliner, and eyeshadow. The earlobes each have two piercings.

The neck is symmetrical and without evidence of injury. The chest is symmetrical. The abdomen is flat. The surface of the back is symmetrical. The external genitalia are those of a normal adult female. The upper and lower extremities are well developed and symmetrical. The great toenails have chipped, black nail polish.

**IDENTIFYING MARKS AND SCARS:** A polychromatic tattoo depicting a purple cross and the text "1917-2007" is on the right shoulder. A polychromatic tattoo depicting a purple paw print and the text "Nitro" is on the midline upper back.

A 2-1/2 inch oblique, linear scar is on the right neck. A 1/2 inch vertical, linear scar is on the midline lower abdomen inferior to the umbilicus. A 6 inch horizontal, linear scar is on the medial lower abdomen, consistent with a Pfannenstiel incision. A 1/8 inch ovoid scar is on the anterior left wrist. A 3-1/2 inch curvilinear scar is on the left knee.

**EVIDENCE OF MEDICAL INTERVENTION:** None.

**EVIDENCE OF INJURY:**

**GUNSHOT WOUNDS OF THE TORSO AND RIGHT LOWER EXTREMITY:**

**A. GUNSHOT WOUND OF THE TORSO:**

**ENTRANCE:** On the right chest, located 16-3/8 inches below the top of the head, 5-1/4 inches to the right of the anterior midline, and 1-1/2 inches lateral to the right nipple, is an entrance gunshot wound consisting of a 1/8 inch circular defect surrounded by an eccentric, circumferential, red-purple marginal abrasion which measures up to 1/8 inch at the 6 o'clock position. The wound margins are irregular with numerous radial microtears. The entrance wound is surrounded by a 5 by 4 inch pink to blue ecchymosis. No soot, stippling, or unburned gunpowder particles are on the skin surrounding the wound.

**PATH AND ASSOCIATED INJURIES:** The bullet perforates the skin and subcutaneous soft tissue of the right chest, the right breast tissue, the anterior right ribs 5-6, the lower lobe of the right lung, the heart, including both atria, both ventricles, and the tricuspid and mitral valves, the lower lobe of the left lung, the lateral left intercostal spaces 7-9 and rib 9, and the subcutaneous soft tissue and skin of the left upper back. The wound track is hemorrhagic and disrupted. The right pleural cavity contains 460 milliliters of liquid and clotted blood. The left pleural cavity contains 140 milliliters of liquid blood.

**EXIT:** On the left upper back, located 17-3/4 inches below the top of the head, 9-1/4 inches below the top of the shoulder, and 5-3/4 inches to the left of the posterior midline, is an exit gunshot wound consisting of a 7/16 inch slit like defect. The wound margin has a 1/16 inch pink abrasion at the 8 to 9 o'clock positions. A 1/8 inch laceration extends inferomedially from the 5 o'clock position. The exit wound is surrounded by a 4-1/2 by 1-1/2 inch pink to green ecchymosis.

**RECOVERY:** A yellow metal jacket fragment and multiple grey metal bullet core fragments are recovered from along the wound track in the left chest.

**CLOTHING:** The right anterior panel of the shirt and the bra have defects corresponding with the entrance wound. The left posterior panel of the shirt has a defect corresponding with the exit wound. No residues are identified on the material surrounding the defects.

**DIRECTION:** The bullet passes from front to back, right to left, and slightly downward.

#### **B. GUNSHOT WOUND OF THE RIGHT THIGH:**

**ENTRANCE:** On the proximal lateral right thigh, located 36 inches below the top of the head and 1/4 inch anterior to the lateral midline of the right thigh, is an entrance gunshot wound consisting of a 1/4 by 3/16 inch ovoid defect surrounded by an eccentric, circumferential, pink-red marginal abrasion which measures up to 3/16 inch at the 9 o'clock position. The entrance wound is surrounded by a 3/4 inch green ecchymosis. No soot, stippling, or unburned gunpowder particles are on the skin surrounding the wound.

**PATH AND ASSOCIATED INJURIES:** The bullet perforates the skin and subcutaneous soft tissue of the anterolateral right thigh. The wound track is disrupted and hemorrhagic.

**EXIT:** On the proximal anterior right thigh, located 33-3/4 inches below the top of the head and in the anterior midline of the right thigh, is an exit gunshot wound consisting of a 3/8 inch circular defect surrounded by an eccentric, circumferential, pink marginal abrasion which measures up to 1/16 inch at the 12 o'clock position. The wound margin is irregular. The exit wound is surrounded by a 3/4 inch pink to blue ecchymosis.

**RECOVERY:** Multiple grey metal bullet core fragments are recovered from along the wound track in the right thigh.

**CLOTHING:** The right anterior panel of the pants has a defect corresponding with the entrance wound. The exit wound has no corresponding clothing defect. No residues are identified on the material surrounding the defect.

**DIRECTION:** The bullet passes from right to left, back to front, and upward.

#### C. GUNSHOT FRAGMENT WOUND OF THE RIGHT THIGH:

This gunshot wound may represent an injury caused by prior fragmentation of the bullet associated with the gunshot wound of the right thigh (GSW B), described above, or it may represent an injury caused by a separate bullet fragment.

**ENTRANCE:** On the proximal posterolateral right thigh, located 36-1/2 inches below the top of the head and 1-1/8 inches posterior to the lateral midline of the right thigh, is an entrance gunshot fragment wound consisting of a 1/8 inch circular defect surrounded by a concentric, circumferential, red marginal abrasion which measures up to 1/16 inch. The entrance wound is surrounded by a faint blue ecchymosis. No soot, stippling, or unburned gunpowder particles are on the skin surrounding the wound.

**PATH AND ASSOCIATED INJURIES:** The bullet fragment perforates the skin and shallowly penetrates the subcutaneous soft tissue of the posterolateral right thigh.

**EXIT:** None.

RECOVERY: A portion of deformed grey metal bullet core is recovered from the right thigh.

CLOTHING: The right posterior panel of the pants has a defect corresponding with the entrance wound. No residues are identified on the material surrounding the defect.

DIRECTION: The bullet passes from right to left.

#### D. GUNSHOT FRAGMENT WOUNDS OF THE RIGHT LEG:

ENTRANCE: On the lateral right leg, located 56-3/4 inches below the top of the head and 1/4 inch anterior to the lateral midline of the right leg, is a pair of entrance gunshot wounds, consisting of a 1/8 inch circular defect surrounded by a concentric, circumferential, red marginal abrasion which measures up to 1/16 inch, and a 1/4 by 3/16 inch ovoid defect surrounded by an eccentric, circumferential, red marginal abrasion which measures up to 1/8 inch at the 3 to 4 o'clock positions. The skin surrounding the two defects has multiple, punctate to 1/8 inch round and ovoid abrasions, which measure up to 2-1/4 inches from the 10 o'clock position (pseudostippling). The entrance wounds are surrounded by a 1-1/4 by 3/4 inch green ecchymosis.

PATH AND ASSOCIATED INJURIES: The bullet fragments perforate the skin and subcutaneous soft tissue, and penetrate the musculature of the lateral right leg.

EXIT: None.

RECOVERY: Multiple grey metal bullet core fragments are recovered from within the wound track in the right leg.

CLOTHING: The distal right leg of the pants has a defect corresponding with the entrance wounds. No residues are identified on the material surrounding the defect.

DIRECTION: The bullet fragments pass from right to left.

BLUNT FORCE INJURIES:

BLUNT FORCE INJURY OF THE HEAD: A 1/2 inch ovoid, red abrasion is on the nasal dorsum.

BLUNT FORCE INJURY OF THE TORSO: A 1/2 inch ovoid, pink contusion is on the right lower quadrant of the abdomen.

BLUNT FORCE INJURY OF THE EXTREMITIES: A 1 inch circular, yellow contusion is on the anterior right arm. A 1/4 inch oblique, linear, red, scabbed abrasion is on the dorsal right wrist, surrounded by multiple punctate, red scabbed abrasions on the posterior right forearm and dorsal right hand. A 1/8 inch red abrasion is on the dorsal right second finger.

Two, 1/2 to 1-1/4 inch ovoid, green to purple contusions and a 1-1/2 by 1/2 inch ovoid, purple-red contusion are on the anterior left thigh. Multiple, 1/4 inch ovoid, brown abrasions are on the dorsal left foot.

Multiple, 1/2 to 1 inch circular, faint, green contusions are on the anterior right thigh. A 1/2 inch oblique, linear, brown, scabbed, interrupted abrasion is on the distal anterior right thigh, surrounded by green contusion. A 1/2 inch circular, purple contusion is on the anterior right leg. A 2 inch oblique, linear, red, scabbed, interrupted abrasion is on the posterior right thigh.

*The injuries above, having been described once, will not be repeated.*

INTERNAL EXAMINATION:

BODY CAVITIES: See EVIDENCE OF INJURY. Easily breakable fibrous adhesions are in the peritoneal cavity. No other adhesions are in the body cavities. All internal organs are in their normal anatomic positions. The serous surfaces, where intact, are smooth and glistening.

HEAD: The subscalp tissues are without hemorrhage. The calvaria is unremarkable. The dura mater and falx cerebri are intact. There is no epidural, subdural, or subarachnoid hemorrhage. The brain weighs 1190 grams and has a normal shape.



The leptomeninges are thin and delicate. The cerebral hemispheres are symmetrical. The structures at the base of the brain, including cranial nerves and blood vessels, are intact. The cerebral cortical ribbon is well demarcated from the white matter. The deep nuclei and ventricles, cerebellum, brainstem, and proximal cervical spinal cord have the standard configuration with no lesions. The remaining spinal cord is not examined.

NECK: The anterior and posterior muscles of the neck are without hemorrhage. The tongue mucosa is intact with no hemorrhage in the musculature. The hyoid bone and thyroid and cricoid cartilages are intact. The laryngeal mucosa is tan and glistening with no edema. The epiglottis is thin with no edema. The atlanto-occipital articulation is stable. No cervical fractures are palpated.

CARDIOVASCULAR SYSTEM: See EVIDENCE OF INJURY. The heart weighs 280 grams and, where intact, has a smooth, glistening epicardial surface with a small amount of epicardial fat. The coronary artery system has patent ostia and a left dominant distribution. Yellow, eccentric atherosclerotic plaques produce up to 20 percent stenosis of the left circumflex and right coronary arteries and up to 30 percent stenosis of the left anterior descending coronary artery. The myocardium, where intact, is red-brown, without pallor, softening, or fibrosis. The wall thickness of the left ventricle is 1.4 centimeters, the right ventricle 0.3 centimeter, and interventricular septum 1.2 centimeters. The endocardial surfaces, where intact, are smooth and without hemorrhage. The remaining intact cardiac valves are thin, freely mobile, and measure as follows: pulmonic valve 7 centimeters and aortic valve 7.5 centimeters. The tricuspid and mitral valves are disrupted; therefore, circumferences cannot be measured. The aorta and its major branches arise normally and follow their usual distribution, with mild atherosclerosis. The venae cavae and their major tributaries return to the heart in their usual distribution and are free of thrombi.

RESPIRATORY SYSTEM: See EVIDENCE OF INJURY. The 340 gram right lung and 220 gram left lung have normal lobation. The pleural surfaces, where intact, are smooth and glistening, with marked anthracotic pigment deposition. The parenchyma has severe emphysematous changes, with bullae at the periphery of the upper lobes. The cut surfaces exude bloody fluid. The pulmonary arterial vasculature is without thromboemboli or significant atherosclerosis.



**HEPATOBIILIARY SYSTEM:** The 1270 gram liver has a smooth, glistening, intact capsule covering dark red to green-brown, firm parenchyma with no focal lesions. The gallbladder contains 2 milliliters of green-brown mucoid bile without stones. The mucosa is velvety and unremarkable. The extrahepatic biliary tree is patent, without evidence of calculi.

**ALIMENTARY SYSTEM:** The esophagus is lined by gray-white, smooth mucosa. The gastric mucosa is unremarkable and the lumen contains 420 milliliters of green-gray pasty material and partially digested food including peppers, mushrooms, and beans, with no alcoholic aromatic odor, granular material, intact pills, or pill fragments. The small intestines and colon are unremarkable. The appendix is not identified. The pancreas has a pink-tan, lobulated appearance and the ducts are clear.

**GENITOURINARY SYSTEM:** The right and left kidneys weigh 70 and 110 grams, respectively. The renal capsules are smooth, thin, and semi-transparent. The underlying cortical surfaces are coarsely granular, with up to 1 centimeter simple cortical cysts. The cortices are pale tan and are sharply delineated from the medullary pyramids, which are pink and unremarkable. The calyces, pelves, and ureters are unremarkable. The urinary bladder contains less than 1 milliliter of clear yellow urine. The mucosa is pink-white and unremarkable. The vaginal mucosa is unremarkable. The vaginal canal ends blindly in a well-healed cuff. The uterus, fallopian tubes, and ovaries are remotely surgically absent.

**RETICULOENDOTHELIAL SYSTEM:** The 70 gram spleen has a smooth, intact capsule and dark red-purple, firm parenchyma. The white pulp is unremarkable. The regional lymph nodes are not enlarged.

**ENDOCRINE SYSTEM:** The thyroid gland has a normal shape and size with uniform, red-brown, rubbery parenchyma. The parathyroid glands are inconspicuous. The adrenal cortices are golden-yellow and uniformly thin, while the medullae are thin and gray.

**MUSCULOSKELETAL SYSTEM:** See EVIDENCE OF INJURY. The vertebrae, clavicles, sternum, and pelvis are without fracture or developmental anomaly. The musculature is normally distributed and unremarkable. The diaphragm is intact.

**RADIOGRAPHS:** Anteroposterior and lateral views show numerous, small projectile fragments in the chest, right thigh, and right leg.

**TOXICOLOGY:** Blood, vitreous fluid, urine, bile, stomach contents, liver, and brain are submitted.

**EVIDENCE:** Clothing, gunshot residue stubs, fingernails scrapings and clippings kit, DNA bloodstain card, bullet and jacket fragments recovered from the left chest, bullet fragments recovered from the right thigh, and bullet fragments recovered from the right leg are submitted.

**HISTOLOGY:** The following sections are submitted: Cassette A – Heart; Cassette B – Lungs; Cassette C – Liver and kidney; Cassette D – Brain.

#### **PATHOLOGICAL FINDINGS**

**I. Gunshot wounds of the torso and right lower extremity**

**A. Gunshot wound of the chest:**

1. Entrance: Right chest, with no soot or stippling
2. Path and associated injuries:
  - a. Perforates right breast, right ribs 5-6, lower lobe of right lung, heart, lower lobe of left lung, left intercostal spaces 7-9 and rib 9, and left upper back
  - b. Bilateral hemothoraces (right, 460 milliliters; left, 140 milliliters)
3. Exit: Left upper back
4. Recovery: Yellow metal bullet jacket fragment and multiple grey metal bullet core fragments from left chest
5. Clothing: Defects corresponding to entrance and exit wounds, with no residues
6. Direction: Front to back, right to left, and slightly downward

**B. Gunshot wound of the right thigh:**

1. Entrance: Proximal lateral right thigh, with no soot or stippling
2. Path and associated injuries:
  - a. Perforates skin and subcutaneous soft tissue of anterolateral right thigh
  - b. Soft tissue hemorrhage

3. Exit: Proximal anterior right thigh
4. Recovery: Multiple grey metal bullet core fragments from right thigh
5. Clothing: Defect corresponding to entrance wound, with no residues
6. Direction: Right to left, back to front, and upward
- C. Gunshot fragment wound of the right thigh:
  1. Entrance: Proximal posterolateral right thigh, with no soot or stippling
  2. Path and associated injuries:
    - a. Perforates skin and penetrates subcutaneous soft tissue of posterolateral right thigh
    - b. Soft tissue hemorrhage
  3. Exit: None
  4. Recovery: Grey metal bullet core fragment from right thigh
  5. Clothing: Defect corresponding to entrance wound, with no residues
  6. Direction: Right to left
- D. Gunshot fragment wounds of the right leg:
  1. Entrance: Lateral right leg, with pseudostippling but no soot or true stippling
  2. Path and associated injuries:
    - a. Perforates skin and subcutaneous soft tissue and penetrates musculature of lateral right leg
    - b. Soft tissue and deep muscular hemorrhage
  3. Exit: None
  4. Recovery: Multiple grey metal bullet core fragments from right leg
  5. Clothing: Defect corresponding to entrance wound, with no residues
  6. Direction: Right to left
- II. Minor blunt force injuries
  - A. Abrasion of the nasal dorsum
  - B. Contusion of the right lower quadrant of the abdomen
  - C. Contusions and abrasions of the right upper extremity and bilateral lower extremities
- III. Additional pathologic findings:
  - A. Mild hypertensive and atherosclerotic cardiovascular disease
    1. Mild coronary artery atherosclerosis
    2. Mild aortic atherosclerosis
    3. Nephroarterio- and arteriolosclerosis
  - B. Severe pulmonary anthracosis and emphysema

Rhogena Ann Nicholas

ML19-0331

-12-

HARRIS COUNTY INSTITUTE OF FORENSIC SCIENCES  
1861 OLD SPANISH TRAIL  
HOUSTON, TEXAS 77054

Marianne E. Beynon, M.D.  
Forensic Pathology Fellow

ML19-0331

MICROSCOPIC EXAMINATION

4 H&E-stained slides are reviewed.

HEART - Mild myocyte hypertrophy; patchy increased perivascular and interstitial fibrosis; patchy interstitial hemorrhage

LUNG - Airspace enlargement with alveolar septal destruction and interstitial fibrosis; marked peribronchial and subpleural anthracotic pigment deposition; intra-alveolar pigment-laden macrophages; no polarizable foreign material

LIVER - Minimal (less than 5%), macrovesicular steatosis; mild, patchy increased chronic portal inflammation

KIDNEY - Scattered sclerotic glomeruli with moderate arterio- and arteriolosclerosis; patchy interstitial fibrosis with mild chronic inflammation; vascular congestion

BRAIN - No significant pathologic change



Marianne E. Beynon, M.D.  
Forensic Pathology Fellow

03/12/19

MMDDYY



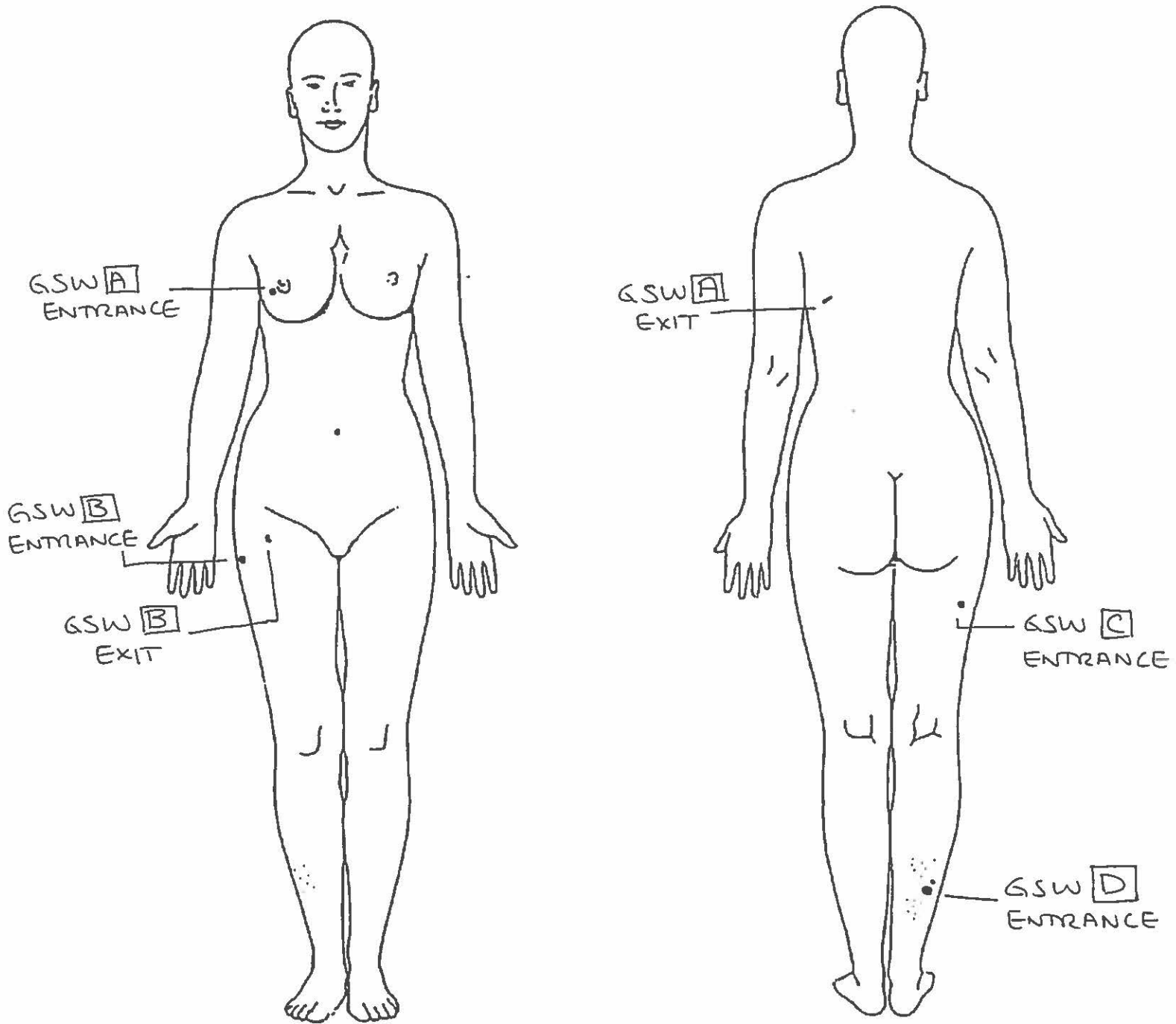




Harris County Institute of Forensic Sciences		CLARIFICATION
Case Number: ML19-0331		Page: 1 of 1
Decedent's Name: RHOGENA NICHOLAS	Length: 69	Weight: 128
Examiner: BEYNON/WOLF	Date: 1/29/19	Time: 9:30 AM

DIAGRAM PREPARED: 2/26/19

GUNSHOT WOUNDS



Section: Pathology	Authorized by: DA Wolf	
Form Title: Autopsy Diagram - Adult Female, Front/ Back	Form No.: PAT.002	MEB
Rev.:	Rev. date: 11/5/13	

# HARRIS COUNTY INSTITUTE OF FORENSIC SCIENCES

1861 Old Spanish Trail  
Houston, TX 77054-2001

Phone: 832-927-5005 FAX: 832-927-2876

## TOXICOLOGY REPORT

March 06, 2019

LABORATORY NUMBER: ML19-0331

SERVICE REQUEST: 0001



Deceased: RHOGENA ANN NICHOLAS

### Submitted By:

Marianne Beynon, M.D.  
Forensic Pathology Fellow  
Harris County Institute of Forensic Sciences  
1861 Old Spanish Trail  
Houston, TX 77054

Submission Date: January 29, 2019

### RESULTS:

#### 001 - Blood (femoral)

Analyte	Result	Analytical Method	Analyst
Benzoylcegonine	0.027 ± 0.004 mg/L	LC/MS/MS	S. Hannon

#### 001 - Blood (femoral)

Analyte	Result	Analytical Method	Analyst
Acetone	None Detected	Headspace GC/FID	A. DeWalt
Ethanol	None Detected	Headspace GC/FID	A. DeWalt
Isopropanol	None Detected	Headspace GC/FID	A. DeWalt
Methanol	None Detected	Headspace GC/FID	A. DeWalt
Amphetamine	None Detected	LC/MS/MS	S. Hannon
Bupropion	None Detected	LC/MS/MS	S. Hannon
Cocaine	None Detected	LC/MS/MS	S. Hannon
Methamphetamine	None Detected	LC/MS/MS	S. Hannon
Methylenedioxymethamphetamine	None Detected	LC/MS/MS	S. Hannon
Phentermine	None Detected	LC/MS/MS	S. Hannon
Pseudoephedrine/Ephedrine	None Detected	LC/MS/MS	S. Hannon

Medical Examiner's Initials and Date MEB 3/6/19

All testing is accredited by the Texas Forensic Science Commission and by the laboratory's ISO/IEC 17025 and American Board of Forensic Toxicology accreditation issued by the ANSI National Accreditation Board.

Refer to certificate and scope of accreditation FT-0076.

We welcome your feedback at <http://ifs.harriscountytexas.gov/Pages/CrimeLaboratoryService.aspx>

Page 1 of 2

HCIFSToxAll v01222019



LABORATORY NUMBER: ML19-0331

DATE: March 6, 2019

SERVICE REQUEST: 0001

**002 - Blood (right chest)**

<u>Analyte</u>	<u>Result</u>	<u>Analytical Method</u>	<u>Analyst</u>
Amphetamine / MDA	None Detected	Immunoassay - ELISA	F. Chavez
Benzodiazepines	None Detected	Immunoassay - ELISA	F. Chavez
Cannabinoids	None Detected	Immunoassay - ELISA	F. Chavez
Carisoprodol	None Detected	Immunoassay - ELISA	F. Chavez
Fentanyl	None Detected	Immunoassay - ELISA	F. Chavez
Methadone	None Detected	Immunoassay - ELISA	F. Chavez
Opiates	None Detected	Immunoassay - ELISA	F. Chavez
Oxycodone	None Detected	Immunoassay - ELISA	F. Chavez
Phencyclidine	None Detected	Immunoassay - ELISA	F. Chavez
Methamphetamine / MDMA	None Detected	Immunoassay - ELISA	F. Chavez

Uncertainty of Measurement: The uncertainty value for ethanol represents an expanded uncertainty expressed at the 99.73% level of confidence. The uncertainty values for all other analytes represent an expanded uncertainty expressed at the 95.45% level of confidence.

Only those items listed in the results section were tested.

Evidence Disposition: All items will be retained by the laboratory for at least one year following the issuance of an original Toxicology Report.

INSTITUTE OF FORENSIC SCIENCES

MAR 06 2019

RECEIVED  
RECORDS CUSTODIAN



Linda Alvarado, BS, C(ASCP), D-ABFT-FT  
Case Reviewer  
Toxicologist II Specialist  
March 06, 2019



Anna Kelly, Ph.D., F-ABFT,  
Expert Reviewer  
Deputy Chief Toxicologist  
March 06, 2019

Medical Examiner's Initials and Date MEB 3/6/19

All testing is accredited by the Texas Forensic Science Commission and by the laboratory's ISO/IEC 17025 and American Board of Forensic Toxicology accreditation issued by the ANSI National Accreditation Board.

Refer to certificate and scope of accreditation FT-0076.

We welcome your feedback at <http://ifs.harriscountytexas.gov/Pages/CrimeLaboratoryService.aspx>